

**Luc PONCELET, DMV, DScV, DECVN**  
 av. Herbert Hoover, 22; 1200 Bruxelles  
 +32 497452084

|                                   |                        |                    |
|-----------------------------------|------------------------|--------------------|
| <b>Patient:</b> Spissinger, Chien | <b>DOB:</b> 5/07/2014  | <b>Physician:</b>  |
| <b>ID#:</b> 972 270000349056      | <b>Height:</b> 60 cm   | <b>Technician:</b> |
| <b>Sex:</b> Male                  | <b>Weight:</b> 33.5 Kg | <b>Ref Phys:</b>   |

**Patient History / Physical Examination:**

**Medications:**

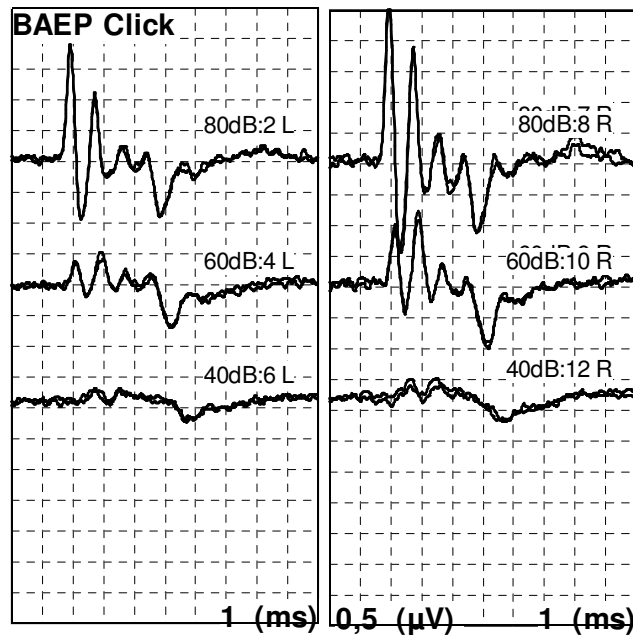
**ELECTRODIAGNOSTIC RESULTS**

**BAEP Click**

| Trace | I (ms) | II (ms) | III (ms) | IV (ms) | V (ms) | I-III (ms) | III-V (ms) | I-V (ms) | V-Va (µV) | I-Ia (µV) |
|-------|--------|---------|----------|---------|--------|------------|------------|----------|-----------|-----------|
| Norm  | <2.0   |         | <4.5     |         | <6.2   | 4          | <2.3       | <        | 4.5       |           |

\* Trace/Trial was acquired with ear insert stimulators. (1 ms. subtracted from latencies)

**WAVEFORMS**



**Patient:** Spissinger, Chien

**Test Date:** 3/09/2016

**p.** 2

**Summary of Findings:**

**Conclusions : Entendant Bilatéral Normal**

*Bruxelles le 3/09/2016*

*Professeur Luc PONCELET,*